Check for updates

RESEARCH ARTICLE

A biobank resource for placental malaria and placental health research

[version 1; peer review: 2 approved with reservations]

Melvin Mbalitsi[1,2*], Mercy Singoei[3], Samuel Chenge[4*], Harrison M. Ngure[1], Paul O. Angienda[2], Moses Madadi Obimbo[3], Bernard N. Kanoi[1], Jesse Gitaka[1], Francis M. Kobia[1]

[1]Centre for Malaria Elimination, Institute of Tropical Medicine, Mount Kenya University, Thika, Kenya
[2]School of Physical and Biological Sciences, Department of Zoology, Maseno University, Maseno, Kenya
[3]Department of Human Anatomy, University of Nairobi, Nairobi, Kenya
[4]Department of Medical Microbiology, School of Biomedical Sciences, Jomo Kenyatta University of Agriculture and Technology College of Engineering and Technology, Juja, Kenya

* Equal contributors

v1 **First published:** 24 Dec 2024, **4**:273
https://doi.org/10.12688/openreseurope.18617.1
Latest published: 24 Dec 2024, **4**:273
https://doi.org/10.12688/openreseurope.18617.1

Abstract

Background

Malaria during pregnancy is a serious threat to maternal and child health in malaria-endemic regions. Malaria during pregnancy often leads to placental malaria, which has severely detrimental effects on fetal outcomes, including fetal growth restriction, preterm delivery, and stillbirth. However, the mechanisms by which placental malaria causes adverse outcomes remain poorly understood. Crucially, there are no tools for detecting and/or intervening in placental malaria during pregnancy. This is mainly because the placenta is inaccessible to research during pregnancy. Nonetheless, its accessibility after delivery offers unique opportunities for studying placental diseases. To support such research, collecting and biobanking naturally-infected placental samples in the geographical context in which diseases of interest occur is crucial.

Methods

Here, we describe the establishment of a biobank of samples obtained from a malaria-endemic region of Kenya, which aims to enhance research capacity in this important but under-studied health

Open Peer Review

Approval Status ? ?

	1	2
version 1 24 Dec 2024	? view	? view

1. **Stephen Rogerson**, University of Melbourne, Melbourne, Australia

2. **Julie M. Moore**, University of Florida, Gainesville, USA

Any reports and responses or comments on the article can be found at the end of the article.

challenge. Histology, PCR, and isothermal identical multirepeat sequence PCR were used to determine the placental malaria status of biobank samples.

Results

Our biobank characterization indicates that placental malaria affects most pregnancies in the malaria-endemic region, despite mothers being asymptomatic during pregnancy and having received anti-malaria chemoprophylaxis. Of the techniques used to detect placental malaria, isothermal identical multirepeat sequence PCR detected the highest number of placental malaria-positive samples (54.2%), compared with placental histology (37.3%), and placenta tissue PCR (17%). However, results from the various techniques did not overlap fully.

Conclusion

Our observations highlight the need to rigorously characterize placental samples from malaria-endemic regions, including by using multiple complementary techniques, even in cases of undetectable malaria during pregnancy. It may also be beneficial to obtain samples from non-malaria-endemic regions for use as placental malaria-naïve controls.

Plain language summary

Malaria infection during pregnancy often leads to the attachment of red blood cells with the malaria parasite to the placenta, seriously threatening the health of the developing baby. However, since the placenta is not accessible during pregnancy, there are no ways of diagnosing placental malaria during pregnancy. Nonetheless, studying the placenta after birth may reveal important biological processes that underlie placental malaria and potentially guide the development of easy-to-use diagnostic tools and effective interventions. To support such research, sample biobanks from women with malaria during pregnancy are crucial. We describe the establishment and characterization of a biobank of samples donated by women with or without malaria during pregnancy to support placental malaria studies and other placenta diseases.

Keywords

Placental malaria, biobank, low-resource settings, maternal and child health

HE This article is included in the Horizon Europe gateway.



This article is included in the European & Developing Countries Clinical Trials Partnership (EDCTP) gateway.

Corresponding author: Francis M. Kobia (kobiafrancis.m@gmail.com)

Author roles: Mbalitsi M: Data Curation, Investigation, Writing – Review & Editing; **Singoei M**: Data Curation, Investigation; **Chenge S**: Data Curation, Investigation, Writing – Review & Editing; **Ngure HM**: Investigation, Writing – Review & Editing; **Angienda PO**: Supervision; **Obimbo MM**: Conceptualization, Data Curation, Resources; **Kanoi BN**: Investigation, Methodology, Resources, Writing – Review & Editing; **Gitaka J**: Conceptualization, Investigation, Methodology, Resources, Writing – Review & Editing; **Kobia FM**: Conceptualization, Data Curation, Formal Analysis, Funding Acquisition, Investigation, Methodology, Project Administration, Resources, Supervision, Visualization, Writing – Original Draft Preparation, Writing – Review & Editing

Competing interests: No competing interests were disclosed.

Grant information: This project (TMA2019CDF-2736) has received funding from the EDCTP2 programme supported by the European Union and Novartis Global Health Basel Switzerland. This project has received funding from the European Union's Horizon Europe research and innovation programme under grant agreement No [TMA2020CDF3203]
The funders had no role in study design, data collection and analysis, decision to publish, or preparation of the manuscript.

Copyright: © 2024 Mbalitsi M *et al*. This is an open access article distributed under the terms of the Creative Commons Attribution License, which permits unrestricted use, distribution, and reproduction in any medium, provided the original work is properly cited.

How to cite this article: Mbalitsi M, Singoei M, Chenge S *et al.* **A biobank resource for placental malaria and placental health research [version 1; peer review: 2 approved with reservations]** Open Research Europe 2024, **4**:273 https://doi.org/10.12688/openreseurope.18617.1

First published: 24 Dec 2024, **4**:273 https://doi.org/10.12688/openreseurope.18617.1

1. Introduction

In 2022, there were an estimated 249 million malaria cases and 608,000 malaria deaths worldwide, most of which occurred in sub-Saharan Africa[1]. Pregnancy is associated with a higher susceptibility to malaria infection[2], and according to the World Health Organization, 12.7 million pregnancies in sub-Saharan Africa were infected with malaria in 2022[1]. Malaria in pregnancy may cause several severe adverse outcomes for the mother and fetus, including maternal anemia and stillbirths[3]. In sub-Saharan Africa, malaria during pregnancy frequently leads to placental malaria, which is characterized by the presence of malaria-infected red blood cells in placental intervillous spaces[4]. *Plasmodium falciparum* (*P. falciparum*) is the most common malaria parasite in sub-Saharan Africa[5], and the cause of the most severe form of malaria[6]. It is also the main cause of placental malaria because of its frequent sequestration in the placenta, which is mediated by the interaction between VAR2CSA on the surface of *P. falciparum*-infected red blood cells and chondroitin sulfate A (CSA) on the syncytiotrophoblast surface[7]. Placental malaria is associated with several adverse effects on the fetus, including low birth weight, preterm birth, and stillbirth[4]. Since malaria transmission to the fetus is thought to be rare[8], such poor outcomes likely result from the effects of placental malaria on the placenta. However, the mechanisms through which placental malaria affects placental physiology and function remain unclear. Moreover, placental malaria and other placental infections are difficult to diagnose and treat because the placenta is inaccessible during pregnancy, a challenge that is further complicated by the fact that many placental infections are asymptomatic[9]. Therefore, considering that placental insults are also thought to affect well-being later in life by contributing to adult-onset chronic diseases, such as cardiovascular disease and type 2 diabetes[10], it is crucial to better understand the placental pathobiology of placental malaria, which may guide the development of diagnostic and therapeutic tools.

Biobanks are key resources in health research. Although widely used research tools, such as immortal cell lines and animal models, are indispensable in health research, they have important limitations. For instance, immortalized cell lines are not sufficiently representative of their corresponding primary cell types in culture, and the *in vivo* environment cannot be fully recapitulated[11], while animal models are limited by fundamental biological differences between humans and other species, ethical concerns, high maintenance costs, and not reproducing human disease with full accuracy[12]. Consequently, the use of human tissues and primary cells to complement these systems is highly attractive as it may offset some of their limitations. These are especially valuable in low-resource settings where the use of cell culture systems and *in vivo* models is limited. Moreover, in such settings, the use of donated tissues for research can allow the study of various diseases in the contexts in which they occur, using naturally infected samples, which would lead to findings that are more physiologically relevant. Despite numerous health challenges, biobanking is insufficient in African countries[13].

Here, we describe a biobank resource established to support placental malaria research. The biobank has placenta, cord, and maternal sera, and maternal and placental dry blood spots donated by women living in malaria-endemic (Western Kenya) and non-malaria-endemic (Central Kenya) regions of Kenya. The rates of asymptomatic malaria are high in Western Kenya[14], which significantly increases the risk of unsuspected malaria during pregnancy and placental malaria. Therefore, we compared the performance of conventional methods (rapid diagnostic tests and PCR) against that of isothermal identical multirepeat sequence (iso-IMRS) PCR[15], an ultrasensitive *P. falciparum* test[16], in the detection of malaria in pregnancy and placental malaria when establishing placental malaria biobanks.

2. Methods

2.1 Participants and sample collection

The biobank's placenta, maternal and cord blood, and maternal and placental dry blood spots were donated by residents of Western Kenya (a malaria-endemic region) and Central Kenya (a malaria non-endemic region). Participants were recruited during antenatal visits or at the time of admission to the maternity ward. Before recruitment, a maternity unit nurse conducted an informed consent process. The nurse explained the study's purpose, procedures, and potential risks and benefits to potential participants in their preferred language (Swahili or their mother tongue). If the participants agreed to participate, they were asked to sign a written informed consent form. The form was available in both Swahili and English, and was read and explained to them in their preferred language. By signing, participants consented to donate placenta, cord blood, and maternal blood samples for use in the current study, as well as in potential future research, without requiring additional consent. The study's participant inclusion criteria were as follows: 1) age ≥18 years, written informed consent, spontaneous vaginal delivery (normal delivery), term delivery, singleton birth, and no known history of sexually transmitted disease during the current pregnancy. Patients who did not meet the inclusion criteria were excluded from the study. Consenting participants were also requested to complete questionnaires that gathered deidentified (using randomly assigned participant numbers) participant details and general data, including maternal age, gravidity, parity, gestational age, history of malaria infection during the current pregnancy, number of antenatal clinic visits, and the number of intermittent presumptive treatments with sulfadoxine-pyrimethamine (IPTp-SP) doses. Figure 1 schematically shows the parent study participant recruitment and biobank establishment. Maternal and cord blood samples were collected before and after delivery, respectively, followed by serum preparation (centrifugation at 2,500 revolutions per minute [rpm] at 4 °C) and preservation at -80 °C. General health information, such as maternal blood pressure and history of diabetes, was also recorded. Newborn-associated data, including sex, birth weight, gestational age, and placental weight, were collected upon delivery. Donated placentas were physically examined according to the recommendations of the Amsterdam Placental Workshop Group[17], followed by the collection of full-thickness biopsies within 30 min of delivery using a standardized approach[18], as schematized in Figure 2B. Histological samples were immediately fixed in 10% formalin for 24 h and then paraffin-embedded, whereas fresh samples were immediately snap-frozen and stored at -80 °C. The placental biopsy strategy

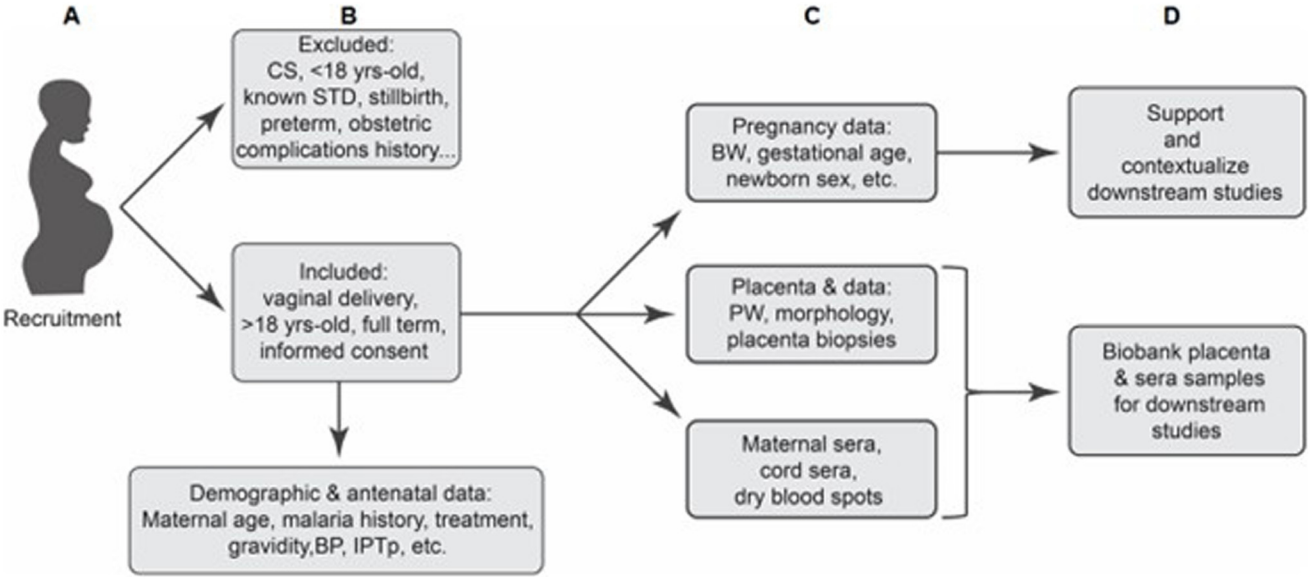

Figure 1. A schematic of sample donor recruitment and underlying biobank data and sample collection. Data and samples were obtained from participants who met the set inclusion criteria and gave written informed consent to participate. CS: cesarean section, STD: sexually transmitted disease, BP: blood pressure, IPTp: intermittent presumptive treatment, PW: placenta weight.

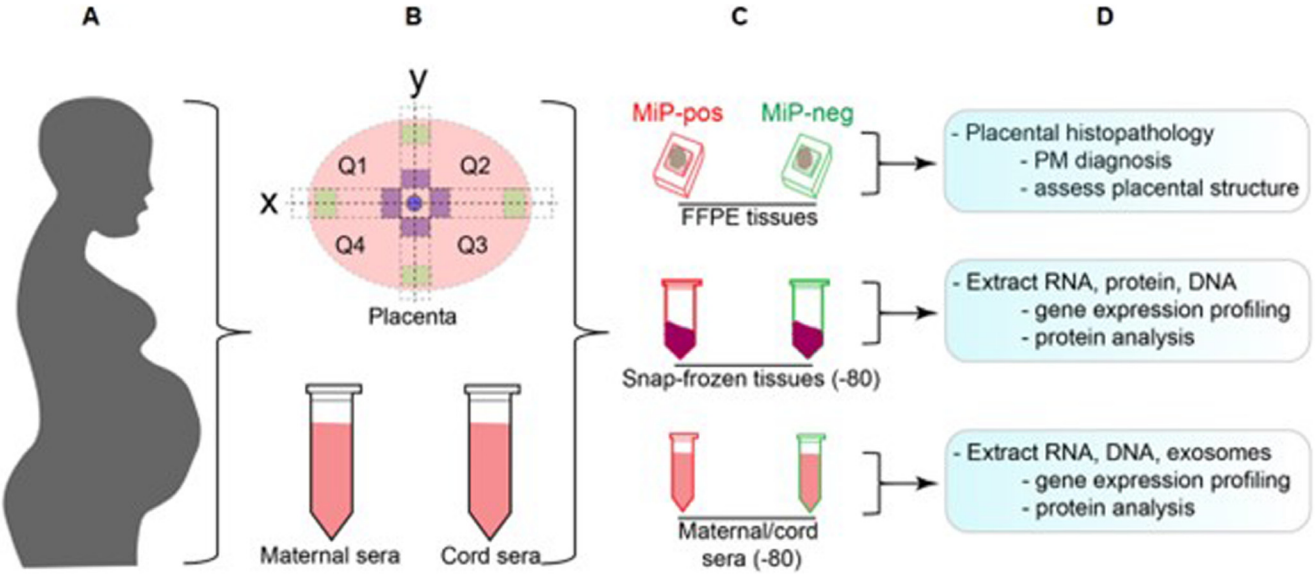

Figure 2. Schematic representation of sample collection for the biobank. A) Samples were donated by residents of a malaria and a non-malaria endemic region of Kenya. **B**) Placentas (upper panel) were biopsied in the four quadrants at the sites coded in green (peripheral) and purple (central). Maternal and cord sera were also obtained (lower panel). The blue spot indicates cord insertion. **C**) Some biopsies were formalin-fixed and embedded, while other biopsies and sera were snap-frozen and stored at -80 °C. **D**) Biobank can support various types of analyses.

and serum and sample storage are shown schematically in Figure 2.

2.2 Histology

Fixed placental biopsies were embedded in paraffin as described previously[19], using a MediMeas embedding system. The presence of infected erythrocytes in placental biopsies was examined using hematoxylin and eosin staining. Briefly, 5-µm-thick placental sections were placed on charged slides (Dako, Cat No. K8020) and then dried overnight on a slide warmer at 37 °C. They were then dewaxed using xylene (Finar Chemicals, Cat No. 21940LC250) and rehydrated through sequential

dipping in absolute, 95%, 70%, and 50% ethanol (Scharlau, Cat No. ET00052500), and distilled water. Next, they were dipped in hematoxylin (Loba Chemie, Cat No. 04023) for seven min and rinsed under running water, followed by destaining in acid alcohol (1% hydrochloric acid in 70% ethanol, 10 dips). The slides were then dipped in eosin (Griffchem, Cat No. 45380) for 45 s, washed in distilled water (one dip), and dehydrated in ethanol (95% and absolute, 10 dips each) before clearance in two xylene washes, five min each. The samples were then coverslipped using dibutylphthalate polystyrene xylene mountant (Finar Chemicals, Cat No. 10525LM250), followed by examination under a microscope (Richter Optica UX1, M2 Scientific) and imaging (40X magnification) in at least 10 fields of view per slide using a Moticam microscope camera (Motic Scientific). Placental malaria status was determined based on the presence of malaria parasite-infected erythrocytes, as described previously[20]. Past placental malaria was indicated by the absence of infected erythrocytes and the presence of fibrin-enmeshed hemozoin and pigmented macrophages[21], while chronic placental malaria was indicated by signs of past placental malaria in the presence of infected erythrocytes[22].

2.3 DNA extraction

Parasite DNA was extracted from dry blood spots (DBS) using the Chelex method, as described previously[23]. Briefly, a 3-mm diameter punch of each DBS was placed into a 1.5 mL microcentrifuge tube, incubated in 1 ml of PBS 1X for 40 min at room temperature, centrifuged at 14,000 rpm for two minutes at 4 °C, and the supernatant discarded. These steps were repeated for a second wash, after which the pellet was resuspended in 50 µL of nuclease-free water. Next, 20 µL of 20% Chelex ®100–sodium (Sigma–Aldrich, Cat. No. 95577) was added to the samples, followed by incubation at 100 °C for 10 min, and centrifugation at 14,000 rpm for one min, at room temperature. The supernatants (containing DNA) were then transferred into new 1.5 mL microcentrifuge tubes and stored at -20 °C.

To extract DNA from placental samples, approximately 10 mg of a cross-sectional placental tissue sample (minced with a sterile scalpel) was placed in a 1.5 mL microcentrifuge tube containing 195 µL of 10% Chelex ®100–sodium and 5 µL of proteinase K (NEB, Cat No. P8107S) and incubated at 60 °C for three h. They were then incubated at 95 °C for 15 min, vortexed briefly, and centrifuged at 14,000 rpm for two min. The supernatants (containing DNA) were then carefully transferred into new microcentrifuge tubes and stored at -20 °C. The extracted DNA was cleaned by precipitation through overnight incubation in a solution of 3 M sodium acetate (ThermoFisher, Cat No. AM9740) and ice-cold absolute ethanol (Scharlau, Cat No. ET00052500) at 0.1 and 2.5 times the sample volumes, respectively. The samples were then centrifuged at 14,000 rpm (4 °C) for 30 min, and the supernatants were discarded. The DNA pellets were then washed twice with 500 µL of ice-cold 70% ethanol (Scharlau, Cat No. ET00052500) and centrifuged at 14,000 rpm for 10 min at 4 °C. After air-drying for 30 min, the DNA pellet was resuspended in 50 µL of nuclease-free water, quantified using a nano-spectrophotometer (Labtron, LNS-C10), and stored at -20 °C.

2.4 PCR analysis

To detect *P. falciparum*, PCR was conducted using the following *P. falciparum*-specific primers (expected band size: 205 bp)[24]: rFAL1 5'-TTAAACTGGTTTGGGAAACCAAATATATT-3' (forward) and rFAL2 5'-ACACAATGAACTCAATCATGACTACCC GTC-3′ (reverse). The following PCR program was used: initial denaturation at 94 °C for 30 s, final denaturation at 94 °C for 30 s, annealing at 51 °C for 45 s, extension at 68 °C for one min, and a final extension at 68 °C for five min. To confirm the PCR results, samples that were negative using the initial PCR were subjected to nested PCR analysis[25] to enhance sensitivity. To this end, a primary PCR was first performed using the primers rPLU6 5'-CTTGTTGTTGCCTTAAACTTC-3' (forward) and rPLU6 5'-TTAAAATTGTTGCAGTTAAAACG-3' (reverse), which produced a 1.2 kb product[26] that was then subjected to the *P. falciparum*-detecting PCR described above (expected band size: 205 bp). The following primary nested PCR program was used: initial denaturation at 94 °C for five min, final denaturation at 94 °C for 30 s, annealing at 55 °C for one min and 15 s, extension at 68 °C for one minute, and a final extension at 68 °C for five min. PCR was performed using One Taq® Quick-Load® 2X Master Mix with standard buffer (NEB, Cat No. M0486S) on a MiniAmp Plus thermal cycler (Applied Biosystems). PCR products were examined using 2% agarose (Cleaver Scientific, Cat No. CSL-AG 100) after staining with SmartGlow™ (Accuris, Cat No. E4500-PS) Fluorescent DNA Dye.

2.5 Identical MultiRepeat Sequence (IMRS) analysis

IMRS is a highly sensitive tool that can detect very low *P. falciparum* densities (asymptomatic) by simultaneously amplifying identical multi-repeat genomic regions[16]. Our group recently coupled this powerful technique with isothermal DNA amplification, which allows the use of a constant IMRS DNA amplification temperature[27] (termed iso-IMRS) for *P. falciparum* DNA detection[15] using the following reagents: Bst 2.0 WarmStart® DNA polymerase (NEB, Cat No. M0538L), isothermal amplification buffer (NEB, Cat No. B0537S), ficoll (Sigma–Aldrich, Cat No. F5415), betaine (Sigma–Aldrich, Cat No. B0300), and dNTPs (NEB, Cat No. N0447S), nuclease-free water (Promega, Cat No. P119E), and forward (5'-CTGGAG-GTCAGTTCACAGTACCC-3') and reverse (5'-CTCTACAATC-CGTAGAGTTACTGG-3') primers, as described previously[15]. The iso-IMRS amplification products were examined using 2% agarose gel (Cleaver Scientific, Cat No. CSL-AG 100) at 100V for 40 min after staining with SmartGlow™ (Accuris, Cat No. E4500-PS) Fluorescent DNA Dye. We used this method to test for *P. falciparum* in the placental tissue, placenta dry blood spots, and maternal dry blood spots.

2.6 Data analyses

GraphPad Prism version 9 was used for statistical analyses and data visualization. The sample size for the analysis comparing the effectiveness of conventional malaria diagnostic tools with that of iso-IMRS in placental malaria detection (Section 3.4) was calculated assuming a confidence level of 95%, a placental malaria population proportion of 54% (based on our placental malaria rate determined using histological analysis of samples from the malaria endemic region), and a population size of 159

(histology-examined placenta samples from the malaria-endemic region).

3. Results

3.1 Placental malaria diagnosis

Hematoxylin and eosin staining was used for placental malaria diagnosis in placental biopsies from 174 donors: 77 with a history of malaria during the current pregnancy and 97 without. Of the donors, 159 and 15 were residents of malaria endemic and non-malaria endemic regions, respectively. Based on histological examination, the biobank placenta samples were classified into placental malaria-negative (no infected erythrocytes observed, n = 54, including 15 from the non-malaria-endemic region), placental malaria-positive (active [at least one infected erythrocyte observed] and chronic-active [at least one infected erythrocyte observed along with fibrin-enmeshed hemozoin and macrophages], n = 92), and past placental malaria (only hemozoin present, n = 28) groups, as described previously[21,22] (Figure 3A–D, Raw data File 1).

3.2 Placental malaria is frequently asymptomatic

At the time of sample donation, participants did not exhibit symptoms associated with malaria and they did not test positive for malaria using rapid diagnostic tests. Almost all placental donors from the malaria-endemic region (97%, Raw data File 1) had received IPTp-SP during pregnancy, although the number of administered doses varied widely (Figure 3A). Moreover, based on histological analysis of the samples from the malaria endemic region, the number of infected erythrocytes in the placentas varied widely (Figure 3B). Analysis of the data stratified by the history of malaria infection during the current pregnancy revealed that 71.4% of the participants who reported a history of malaria during the current pregnancy also had placental malaria, as revealed by histological examination, while 9.1% of the cases exhibited signs of past placental malaria infection (Figure 3C), which was indicated by the presence of hemozoin (malaria pigment) but not infected erythrocytes (Figure 4). Importantly, this analysis showed that among those who reported having no history of malaria during the current

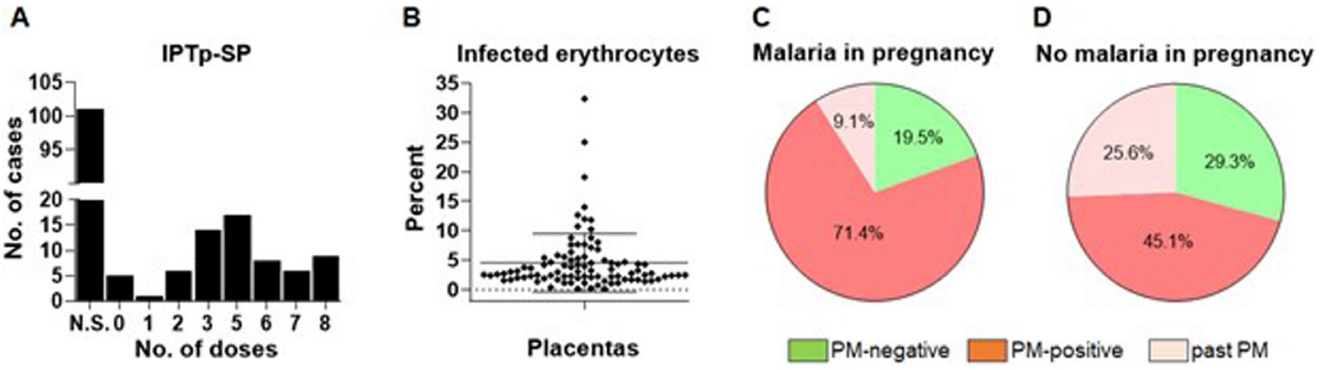

Figure 3. Most residents of the malaria endemic region had placental malaria (PM). A) Characterization of the data underlying the biobank revealed that frequency of anti-malaria chemoprophylaxis varied widely among the sample donors. N.S.: number of IPTp-SP (intermittent presumptive treatment with sulfadoxine-pyrimethamine) doses not specified. **B**) Histological analysis indicates that the number of infected erythrocytes varies widely across asymptomatic placenta malaria cases. **C**–**D**) Histological analysis indicated that the majority of cases with (**C**) or without (**D**) a history of malaria in pregnancy had ongoing or past placental malaria.

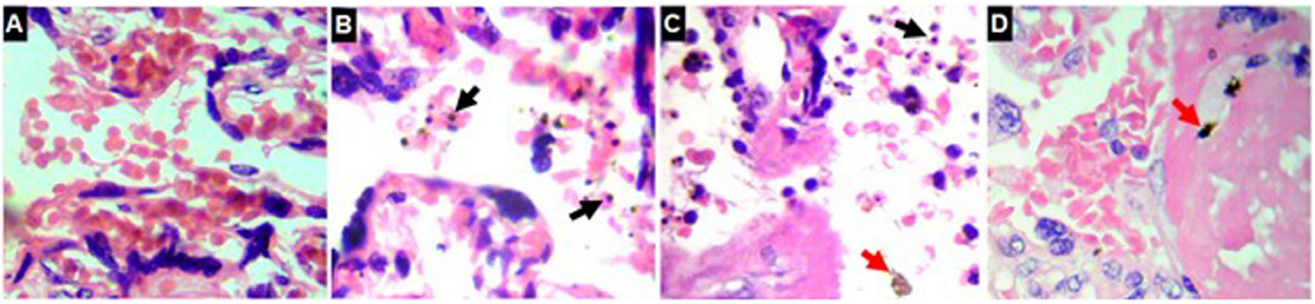

Figure 4. Histological analysis was used to diagnose and classify placental malaria. A) Hematoxylin and eosin (H&E) staining of a placental malaria-free sample. **B**) H&E shows an active case of placental malaria (black arrow: infected erythrocytes). **C**) H&E shows a case of chronic-active placental malaria (black arrow: infected erythrocytes, red arrow: hemozoin). **D**) H&E shows a case of past placental malaria (red arrows: fibrin-entrapped hemozoin).

pregnancy, 45.1% had placental malaria, while 25.6% exhibited past placental malaria (Figure 3D). Taken together, these data indicate that placental malaria is frequent even in the absence of overt malaria symptoms during pregnancy.

3.3 Conventional techniques fail to detect some placental malaria cases

Participants were grouped into malaria in pregnancy and non-malaria in pregnancy groups based on their response to the question of whether they had at least one microscopy-confirmed malaria episode during the current pregnancy (before recruitment into this study). Moreover, during sample donation, rapid malaria diagnostic tests, which are widely used in endemic regions[28], did not detect malaria infection in any of the participants. Because of the constraints in the low-resource settings where the samples were collected, it was not feasible to use microscopy, the gold standard for malaria diagnosis[29], to examine maternal blood films at the time of recruitment and sample collection. However, because rapid diagnostic tests and microscopy frequently fail to detect placental malaria[29], we collected maternal dry blood spots for downstream PCR-based malaria diagnosis, which is highly sensitive[30].

3.4. A comparison of conventional methods identifies iso-IMRS as a highly sensitive placental malaria diagnostic tool

Since rapid diagnostic testing at the time of sample donation did not detect maternal malaria in the sample donors, and yet, histology, the gold standard for placental malaria diagnosis[4], revealed infected erythrocytes in most placentas, we wondered how the efficiency of histology-based placental malaria diagnosis compared with that of rapid diagnostic tests and PCR. The comparison was performed using 59 samples (the sample size was determined as described in Section 2.6), of which, based on histology, 22 (37.3%) and 37 (62.7%) were placental malaria positive and negative, respectively. A higher number of placental malaria negative samples (based on histology) was included to better assess if and at which rate, histology might miss placental malaria positive cases. Compared with rapid diagnostic tests, which did not detect any malaria in pregnancy cases (Figure 5A), PCR analysis of the maternal dry blood spots detected eight (13.6%) *P. falciparum*-positive cases (Figure 5B; a representative PCR image is shown in Figure 5K). Of these, two cases were positive for placental malaria based on histology (Raw data File 2). This indicates that rapid tests miss asymptomatic malaria in pregnancy and that during pregnancy, they are not a reliable indicator of ongoing placental malaria. Next, we examined how placental histology compared with PCR analyses of placental blood and tissue. This analysis revealed that PCR analysis of placental dry blood spots detected *P. falciparum* DNA in 13 of the 59 samples (22%), and of the 13, seven also had histology-confirmed placental malaria (Figure 5D) while six were malaria in pregnancy positive based on maternal dry blood spot PCR (Raw data File 2). PCR analysis of DNA extracted from placental tissues detected *P. falciparum* DNA in 10 of the 59 samples (17%), of which, five were placental malaria positive based on histology (Figure 5E), four were positive for malaria in pregnancy based on maternal dry blood spot PCR, and six were *P. falciparum* positive based on placental dry blood spot PCR (Raw data File 2).

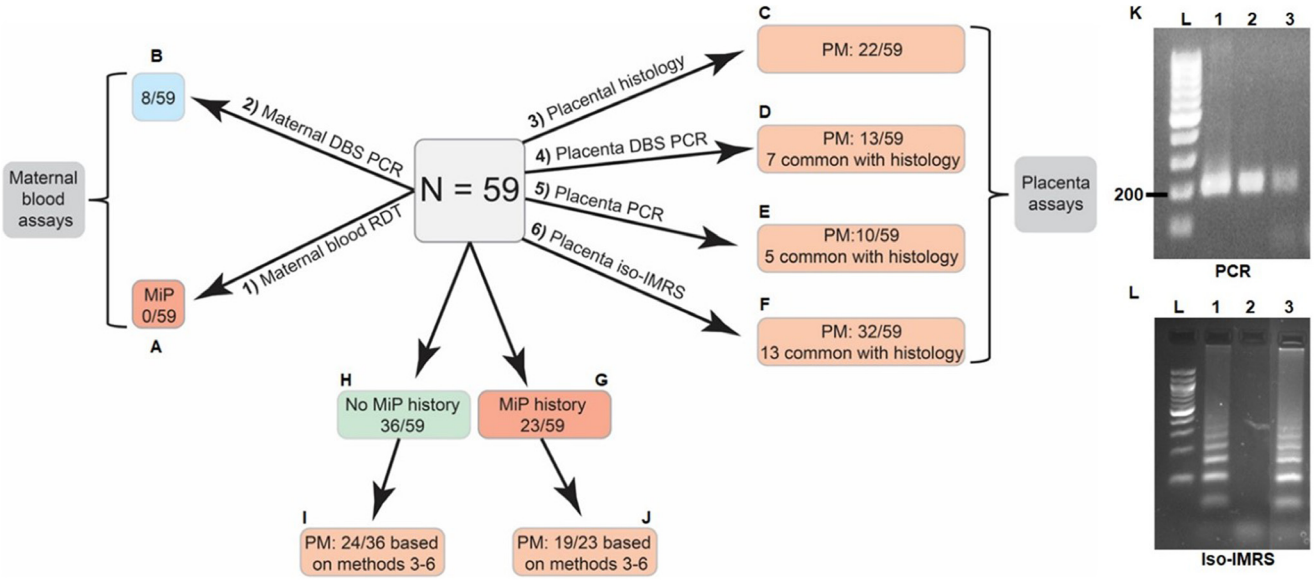

Figure 5. A comparison of the efficiencies of various tools in malaria in pregnancy (MiP) detection. A–B) Rapid diagnostic tests (RDT) vs PCR analysis of maternal blood (DBS: dry blood spot). **C**) Placenta tissue histology. **D–E**) Placenta blood and tissue PCR. **F**) Placenta tissue iso-IMRS (isothermal identical multirepeat sequence analysis). **G–J**) Combined, these approaches (3–6) detected placental malaria in 43 (72.9%) of the analyzed samples. **K–L**) representative images of *P. falciparum* detection in placenta tissue biopsies using PCR (K; PCR product: 205 base pair; L: ladder, 1: positive control DNA sample, 2: dry blood spot DNA sample, 3: placenta tissue DNA sample), and iso-IMRS (L, L: 100 base pair ladder, 1: positive control DNA sample, 2: negative control sample, 3: placenta DNA sample), which generates amplicons of various sizes because multiple sequences are targeted.

PCR analysis of *P. falciparum* using IMRS has been proposed as a highly sensitive means of detecting asymptomatic malaria[16]. Recently, our group coupled isothermal amplification and IMRS to develop iso-IMRS, an ultrasensitive *P. falciparum* detection tool that is highly suitable for low-resource settings[31]. Therefore, we investigated whether iso-IMRS could detect placental malaria more sensitively than conventional approaches. Remarkably, iso-IMRS detected *P. falciparum* DNA in 32 of the 59 placentas examined (54.2%; Figure 5F; Figure 5K shows a representative image of iso-IMRS results), including 13 that were placental malaria positive based on histology and 19 that were placental malaria negative based on histology (Raw data File 2). These data indicate that iso-IMRS is more sensitive than conventional tools for detecting placental malaria. Combined, histology, placental dry blood spot PCR, placental tissue PCR, and iso-IMRS indicated that 43 of the 59 placentas (72.9%) were affected by placental malaria (Figure 5G–J, Raw data File 2).

4. Discussion

Pregnancy is associated with an increased risk of infection by various pathogens, which may result in severely adverse pregnancy outcomes[32]. However, the mechanisms through which such infections disrupt placental health and function are unclear, limiting the ability to diagnose and intervene against placental infections during pregnancy[9]. This is partly because placental infections occur disproportionately in resource-limited settings, which have significant research capacity constraints, and because the placenta is inaccessible for research during pregnancy. Nonetheless, biobanks of naturally infected samples from endemic regions may offer vital resources for bridging crucial research gaps.

In malaria-endemic regions, placental malaria, which is characterized by the sequestration of malaria parasite-infected erythrocytes (mainly *P. falciparum*) in placental intervillous spaces, is associated with poor pregnancy outcomes, including fetal growth restriction, preterm birth, and stillbirth[4]. However, the mechanisms by which placental malaria affects placental health and function are unclear, and currently, no tools are available for placental malaria detection and treatment during pregnancy. Here, focusing on placental malaria, we describe the establishment of a biobank to support placental health studies in resource-limited contexts.

As adult residents of malaria-endemic regions possess partial immunity[33], many cases are asymptomatic[14], making it difficult to accurately identify patients with malaria. This challenge is exacerbated by the fact that microscopy, the gold standard for malaria diagnosis, is subjective, labor- and skill-intensive[34], and relatively cost-intensive in resource-limited settings. Consequently, here, rapid diagnostic tests, which are the main malaria testing tools in Africa[28], were used to screen for malaria in pregnancy cases during sample donor recruitment. However, these tests did not detect any malaria-positive cases in those with or without a known history of malaria infection during pregnancy. This was probably because rapid tests are prone to false-negative readings in cases of low parasite-density or asymptomatic malaria[35,36], which is common in malaria-endemic regions and is estimated to be present in over 80% of residents of highly endemic regions[36], or deletions of the target proteins, HRP2/3[37]. Moreover, in such cases, parasite levels are often below the limit of microscopic detection[36], while driving significant chronic pathogenesis, including in pregnant women[38]. Indeed, PCR analysis of maternal dry blood spots identified malaria in pregnancy cases that were missed by rapid diagnostic tests (Figure 5A–B), indicating that the use of more sensitive techniques, such as nucleic acid-based assays, to detect malaria in pregnancy is critical for placental malaria research and clinical purposes.

Importantly, histological examination revealed that 120 (75.5%) of the 159 placentas from the malaria-endemic region, including those without a known history of malaria during pregnancy, were affected by placental malaria (92 active and 28 past cases, Raw data File 1). Crucially, almost all sample donors had received malaria chemoprophylaxis during pregnancy, although the number of doses used varied widely, and the burden of infected erythrocytes was highly variable across placentas (Figure 4A–B). Therefore, such variables should be considered in studies on placental malaria. Moreover, for research and clinical purposes, it may be important to accurately identify past placental malaria cases because hemozoin, a hallmark of chronic-active and past placental malaria[22], is reported to be immunomodulatory[39]. Together, these observations indicate that in malaria endemic areas, even with chemoprophylaxis, the burden of placental malaria is remarkably high in asymptomatic malaria in pregnancy cases, including those found to be malaria negative using rapid diagnostic tests, which in Africa are used to test up to 87% of suspected malaria cases[28].

Although histology is the gold standard for placental malaria diagnosis[4], the biopsies examined represent a very small proportion of the whole placenta, which, especially in cases with low parasite densities, may lead to false-negative findings because infected erythrocytes may be absent in the randomly sampled area but present in other parts of the placenta. Because nucleic acid amplification is highly sensitive, we compared its *P. falciparum* detection efficiency in 59 placental biopsies and placental blood samples with that of histological analysis (Figure 5C–E). Placental dry blood spot PCR detected *P. falciparum* in 13 samples, compared with 22 based on histology, indicating that histology is superior. However, only seven cases were common between the two methods. Considering that placental biopsies are quite small relative to placenta size, it is likely that placental DBS preparations sampled unique areas that contained parasites. Similarly, PCR analysis of placental tissue biopsies detected *P. falciparum* DNA in 10 of the 59 samples examined, including five that were not detected by histology. These additional cases may have resulted from PCR detection of *P. falciparum* DNA on hemozoin[40] in samples with hemozoin only, which were classified as past placental malaria based on histology.

As it simultaneously amplifies numerous repeats of a genomic sequence, *P. falciparum* IMRS PCR is an ultrasensitive tool for malaria diagnosis[16], and when coupled with isothermal amplification (iso-IMRS), it may be deployed in resource-limited point-of-care settings. The detection of *P. falciparum* DNA using iso-IMRS PCR in tissue biopsies from 32 of 59 placentas

(Figure 5F) highlights iso-IMRS as the most sensitive tool for placental malaria detection. Of the 32 *P. falciparum*-positive cases, 13 were also identified by histology, indicating that relative to histology, iso-IMRS detected markedly more unique cases than placenta dry blood spots and placenta tissue PCR. This is attributable to the higher sensitivity of iso-IMRS, which may have facilitated *P. falciparum* DNA detection in tissues with very low parasite densities or in cases of past placental malaria, with very low levels of parasite DNA in hemozoin deposits. Taken together, our observations indicate that iso-IMRS is the most sensitive tool for placental malaria detection, followed by histology and PCR. Importantly, considering that the results obtained using different techniques did not overlap fully, when using a single technique, it is necessary to extensively sample the placenta to reduce the likelihood of false negative findings. Alternatively, combining histology and iso-IMRS may achieve high placental malaria detection rates, which would be highly valuable for the accurate characterization of placental samples in placental malaria research. Finally, considering that most placental samples from our malaria endemic region had ongoing or past placental malaria, when setting up biobanks, it may be highly beneficial to include samples from a non-malaria-endemic region for use as placental malaria-naïve controls. However, such control samples should undergo similar rigorous characterization.

Ethics statement

This study was approved by Mount Kenya University's Ethics Review Committee, approval number 1314 (date: 17.06.2022) and was conducted in adherence to the Declaration of Helsinki guidelines.

Consent to participate

All study participants gave written informed consent.

Data availability

Raw data

The study's raw data have been deposited in the open science framework data repository, project name: MelvinM *et al.* 2024 raw data files (doi: 10.17605/OSF.IO/U26AC)[41]. The study includes the following data: 1) Raw data file 1_MelvinM *et al.* 2024, 2) Raw data file 2_MelvinM *et al.* 2024. The raw data include information on history of malaria in pregnancy, malaria chemoprophylaxis, placental malaria status, placental infected erythrocyte rates, and comparison of PCR, iso-IMRS and histology in placental malaria detection. The data are shared under a CC-By Attribution 4.0 International license.

Acknowledgements

We thank our study participants and staff at Webuye County and Mary Help of the Sick (Thika) Hospitals for their generous support. We thank the staff of the histopathology and anatomy departments at the University of Nairobi and Mount Kenya University for their help with histology. We are grateful to KAVI–ICR for kindly sharing laboratory space and resources. F.M.K. is supported by the EDCTP2 program of the European Union and Novartis Global Health, Basel – Switzerland, Grant Number TMA2019CDF2736. B.N.K. is an EDCTP Fellow under the EDCTP2 program supported by the European Union grant number TMA2020CDF3203.

References

1. World Health Organization: **World malaria report 2023.** 2023.
Reference Source
2. Fried M, Duffy PE: **Malaria during pregnancy.** *Cold Spring Harb Perspect Med.* 2017; **7**(6): a025551.
PubMed Abstract | Publisher Full Text | Free Full Text
3. Bauserman M, Conroy AL, North K, *et al.*: **An overview of malaria in pregnancy.** *Semin Perinatol.* 2019; **43**(5): 282–290.
PubMed Abstract | Publisher Full Text | Free Full Text
4. Zakama AK, Ozarslan N, Gaw SL: **Placental malaria.** *Curr Trop Med Rep.* 2020; **7**(4): 162–71.
PubMed Abstract | Publisher Full Text | Free Full Text
5. Snow RW, Omumbo JA: **Malaria.** *Disease and mortality in Sub-Saharan Africa.* 2006.
PubMed Abstract
6. Trampuz A, Jereb M, Muzlovic I, *et al.*: **Clinical review: severe malaria.** *Crit Care.* 2003; **7**(4): 315–23.
PubMed Abstract | Publisher Full Text | Free Full Text
7. Ma R, Lian T, Huang R, *et al.*: **Structural basis for placental malaria mediated by *Plasmodium falciparum* VAR2CSA.** *Nat Microbiol.* 2021; **6**(3): 380–391.
PubMed Abstract | Publisher Full Text | Free Full Text
8. Harrington WE, Duffy PE: **Congenital malaria: rare but potentially fatal.** *Ped Health.* 2008; **2**(2): 235–48.
Publisher Full Text | Free Full Text
9. Chenge S, Ngure H, Kanoi BN, *et al.*: **Infectious and environmental placental insults: from underlying biological pathways to diagnostics and treatments.** *Pathog Dis.* 2023; **81**: ftad024.
PubMed Abstract | Publisher Full Text
10. Thornburg KL, Marshall N: **The placenta is the center of the chronic disease universe.** *Am J Obstet Gynecol.* 2015; **213**(4 Suppl): S14–20.
PubMed Abstract | Publisher Full Text | Free Full Text
11. Kaur G, Dufour JM: **Cell lines: valuable tools or useless artifacts.** *Spermatogenesis.* 2012; **2**(1): 1–5.
PubMed Abstract | Publisher Full Text | Free Full Text
12. Hartung T: **Thoughts on limitations of animal models.** *Parkinsonism Relat Disord.* 2008; **14 Suppl 2**: S81–3.
PubMed Abstract | Publisher Full Text
13. Croxton T, Jonathan E, Suleiman K, *et al.*: **Building blocks for better biorepositories in Africa.** *Genome Med.* 2023; **15**(1): 92.
PubMed Abstract | Publisher Full Text | Free Full Text
14. Idris ZM, Chan CW, Kongere J, *et al.*: **High and heterogeneous prevalence of asymptomatic and sub-microscopic malaria infections on Islands in Lake Victoria, Kenya.** *Sci Rep.* 2016; **6**: 36958.
PubMed Abstract | Publisher Full Text | Free Full Text
15. Kolluri N, Kamath S, Lally P, *et al.*: **Development and clinical validation of Iso-IMRS: a novel diagnostic assay for *P. falciparum* malaria.** *Anal Chem.* 2021; **93**(4): 2097–105.
PubMed Abstract | Publisher Full Text | Free Full Text
16. Raju LS, Kamath S, Shetty MC, *et al.*: **Genome mining-based identification of identical multirepeat sequences in *Plasmodium falciparum* genome for highly sensitive real-time quantitative PCR assay and its application in malaria diagnosis.** *J Mol Diagn.* 2019; **21**(5): 824–38.
PubMed Abstract | Publisher Full Text
17. Khong TY, Mooney EE, Ariel I, *et al.*: **Sampling and definitions of placental lesions: amsterdam placental workshop group consensus statement.** *Arch Pathol Lab Med.* 2016; **140**(7): 698–713.
PubMed Abstract | Publisher Full Text
18. Roberts VHJ, Gaffney JE, Lewandowski KS, *et al.*: **A standardized method for collection of human placenta samples in the age of functional magnetic resonance imaging.** *Biotechniques.* 2019; **67**(2): 45–9.
PubMed Abstract | Publisher Full Text | Free Full Text

19. Canene-Adams K: **Preparation of formalin-fixed paraffin-embedded tissue for immunohistochemistry.** *Methods Enzymol.* 2013; **533**: 225–33.
PubMed Abstract | Publisher Full Text

20. Odongo CO, Odida M, Wabinga H, *et al.*: **Burden of placental malaria among pregnant women who use or do not use intermittent preventive treatment at Mulago Hospital, Kampala.** *Malar Res Treat.* 2016; **2016**: 1839795.
PubMed Abstract | Publisher Full Text | Free Full Text

21. Muehlenbachs A, Nabasumba C, McGready R, *et al.*: **Artemether-lumefantrine to treat malaria in pregnancy is associated with reduced placental haemozoin deposition compared to quinine in a randomized controlled trial.** *Malar J.* 2012; **11**: 150.
PubMed Abstract | Publisher Full Text | Free Full Text

22. Rogerson SJ, Hviid L, Duffy PE, *et al.*: **Malaria in pregnancy: pathogenesis and immunity.** *Lancet Infect Dis.* 2007; **7**(2): 105–17.
PubMed Abstract | Publisher Full Text

23. Simon N, Shallat J, Williams Wietzikoski C, *et al.*: **Optimization of Chelex 100 resin-based extraction of genomic DNA from dried blood spots.** *Biol Methods Protoc.* 2020; **5**(1): bpaa009.
PubMed Abstract | Publisher Full Text | Free Full Text

24. Ayala E, Lescano AG, Gilman RH, *et al.*: **Polymerase chain reaction and molecular genotyping to monitor parasitological response to anti-malarial chemotherapy in the Peruvian Amazon.** *Am J Trop Med Hyg.* 2006; **74**(4): 546–53.
PubMed Abstract | Publisher Full Text

25. Wang B, Han SS, Cho C, *et al.*: **Comparison of microscopy, nested-PCR, and real-time-PCR assays using high-throughput screening of pooled samples for diagnosis of malaria in asymptomatic carriers from areas of endemicity in Myanmar.** *J Clin Microbiol.* 2014; **52**(6): 1838–45.
PubMed Abstract | Publisher Full Text | Free Full Text

26. Snounou G, Singh B: **Nested PCR analysis of *Plasmodium* parasites.** *Methods Mol Med.* 2002; **72**: 189–203.
PubMed Abstract | Publisher Full Text

27. Kim J, Easley CJ: **Isothermal DNA amplification in bioanalysis: strategies and applications.** *Bioanalysis.* 2011; **3**(2): 227–39.
PubMed Abstract | Publisher Full Text

28. Kavanaugh MJ, Azzam SE, Rockabrand DM: **Malaria rapid diagnostic tests: Literary review and recommendation for a quality assurance, quality control algorithm.** *Diagnostics (Basel).* 2021; **11**(5): 768.
PubMed Abstract | Publisher Full Text | Free Full Text

29. Mathison BA, Pritt BS: **Update on malaria diagnostics and test utilization.** *J Clin Microbiol.* 2017; **55**(7): 2009–2017.
PubMed Abstract | Publisher Full Text | Free Full Text

30. Oyegoke OO, Maharaj L, Akoniyon OP, *et al.*: **Malaria diagnostic methods with the elimination goal in view.** *Parasitol Res.* 2022; **121**(7): 1867–85.
PubMed Abstract | Publisher Full Text | Free Full Text

31. Kolluri N, Kamath S, Lally P, *et al.*: **Development and clinical validation of Iso-IMRS: a novel diagnostic assay for *P. falciparum* malaria.** *Anal Chem.* 2021; **93**(9): 2097–2105.
PubMed Abstract | Publisher Full Text | Free Full Text

32. Chan MY, Smith MA: **Infections in pregnancy.** *Comprehensive Toxicology.* 2018; **5**: 232–249.
Publisher Full Text

33. Snow RW, Omumbo JA, Lowe B, *et al.*: **Relation between severe malaria morbidity in children and level of *Plasmodium falciparum* transmission in Africa.** *Lancet.* 1997; **349**(9066): 1650–4.
PubMed Abstract | Publisher Full Text

34. Slater L, Ashraf S, Zahid O, *et al.*: **Current methods for the detection of *Plasmodium* parasite species infecting humans.** *Curr Res Parasitol Vector Borne Dis.* 2022; **2**: 100086.
PubMed Abstract | Publisher Full Text | Free Full Text

35. Parr JB, Kieto E, Phanzu F, *et al.*: **Analysis of false-negative rapid diagnostic tests for symptomatic malaria in the Democratic Republic of the Congo.** *Sci Rep.* 2021; **11**(1): 6495.
PubMed Abstract | Publisher Full Text | Free Full Text

36. Hartley MA, Hofmann N, Keitel K, *et al.*: **Clinical relevance of low-density *Plasmodium falciparum* parasitemia in untreated febrile children: a cohort study.** *PLoS Med.* 2020; **17**(9): e1003318.
PubMed Abstract | Publisher Full Text | Free Full Text

37. Nyataya J, Waitumbi J, Mobegi VA, *et al.*: ***Plasmodium falciparum* histidine-rich protein 2 and 3 gene deletions and their implications in Malaria control.** *Diseases.* 2020; **8**(2): 15.
PubMed Abstract | Publisher Full Text | Free Full Text

38. Chen I, Clarke SE, Gosling R, *et al.*: **"Asymptomatic" malaria: a chronic and debilitating infection that should be treated.** *PLoS Med.* 2016; **13**(1): e1001942.
PubMed Abstract | Publisher Full Text | Free Full Text

39. Pham TT, Lamb TJ, Deroost K, *et al.*: **Hemozoin in malarial complications: more questions than answers.** *Trends Parasitol.* 2021; **37**(3): 226–39.
PubMed Abstract | Publisher Full Text

40. Parroche P, Lauw FN, Goutagny N, *et al.*: **Malaria hemozoin is immunologically inert but radically enhances innate responses by presenting malaria DNA to Toll-like receptor 9.** *Proc Natl Acad Sci U S A.* 2007; **104**(6): 1919–24.
PubMed Abstract | Publisher Full Text | Free Full Text

41. Mbalitsi M, Chenge S, Ngure H, *et al.*: **MelvinM *et al.* 2024 associated files.** *Open Science Framework*. 2024.
http://www.doi.org/10.17605/OSF.IO/U26AC

Open Peer Review

Current Peer Review Status: ? ?

Version 1

Reviewer Report 26 February 2025

https://doi.org/10.21956/openreseurope.20139.r49874

© **2025 Moore J.** This is an open access peer review report distributed under the terms of the Creative Commons Attribution License, which permits unrestricted use, distribution, and reproduction in any medium, provided the original work is properly cited.

?

Julie M. Moore
University of Florida, Gainesville, USA

Mbalitsi et al describe a set of blood and tissue samples collected from pregnant/parturient women recruited in two regions of Kenya with different levels of malaria endemicity. Application of multiple means of detecting malaria parasites in maternal blood, placental blood and placental tissue lend significant rigor to the study, and the significant lack of concordance across these various testing methods (rapid diagnostic test(s?), placental histology, peripheral and placental blood PCR and isothermal amplification combined with identical multirepeat sequence analysis) emphasize both the need to apply more than one method to detect parasitemia in these complex samples, and raise important questions about the biological and clinical relevance of difficult to detect parasitemia. The latter point is important for this study as no relationships with maternal or infant outcomes were described, representing a significant limitation of the study. Finally, the title suggests the establishment of a biorepository, but important details thereto are not provided.

Minor comments:

1. How was gestational age of newborns ascertained?
2. As written, section 3.2 is confusing. The opening sentence suggests that all women were asymptomatic. Moreover, the authors should not confuse asymptomatic malaria with self-reported malaria or lack thereof. It is possible that a women might simply not recall symptoms and self-report having had no malaria, which is not the same as asymptomatic malaria. This same concern applies to section 3.4.
3. Figure 4 histology images are low quality.
4. How placental blood for dried blood spots was sampled should be described.

Major comments:

1. It is noted that samples were fixed in 10% formalin. Non-buffered formalin is commonly contaminated with formalin crystals that can be difficult to distinguish from malaria hemozoin microscopically. Can the authors confirm that this is not an issue in their samples?
2. The authors claim that all participants were rapid diagnostic test negative. There is no

information about the test(s) that was used. This is very important information to enable assessment of the reliability of RDTs in this setting.

3. The authors refer to samples as placental malaria positive as long as at least one test was able to detect parasite-infected RBCs (histology) or parasite DNA (molecular approaches). Can the authors provide some commentary as to what they believe the definition of "placental malaria" should be given the level of discordance they have observed among these tests? In general, it seems likely that parasitemias were quite low in this population, based on all information provided and comments by the authors; given that, what is the clinical relevance of such (presumably) low parasitemias? There are no outcome data offered for maternal and infant outcomes (e.g., anemia, birth weight, gestational age) so it is not possible for the reader to make this judgement for themselves.
4. Finally, the title suggests that the authors have created a biorepository but limited information about the content and intent for use of and access to this biorepository is provided. The samples collected and potential uses for them (?; Figure 2) are described, but questions remain: i) is this biorepository intended to be a resource for the scientific community? ii) if so, what samples are/will be available? iii) how many of each sample type have been preserved?

Is the work clearly and accurately presented and does it cite the current literature?
Yes

Is the study design appropriate and does the work have academic merit?
Yes

Are sufficient details of methods and analysis provided to allow replication by others?
No

If applicable, is the statistical analysis and its interpretation appropriate?
Yes

Are all the source data underlying the results available to ensure full reproducibility?
Yes

Are the conclusions drawn adequately supported by the results?
Partly

Competing Interests: No competing interests were disclosed.

Reviewer Expertise: malaria during pregnancy and placental malaria pathogenesis

I confirm that I have read this submission and believe that I have an appropriate level of expertise to confirm that it is of an acceptable scientific standard, however I have significant reservations, as outlined above.

Reviewer Report 29 January 2025

https://doi.org/10.21956/openreseurope.20139.r49878

© 2025 Rogerson S. This is an open access peer review report distributed under the terms of the Creative Commons Attribution License, which permits unrestricted use, distribution, and reproduction in any medium, provided the original work is properly cited.

?

Stephen Rogerson
University of Melbourne, Melbourne, Australia

Mbalitsi and colleagues describe establishing a placental biobank in Kenya. They further evaluate multiple techniques for evaluating the placental samples for presence of malaria. In the cohort they study, despite apparently quite extensive use of IPTp, many women still have active malaria infections at delivery, questioning the antimalarial efficacy of SP in this setting.

The question of what constitutes “placental malaria” is one of the topics the paper covers. While molecular analyses of placental blood can yield useful information, I would advise caution before proposing that a molecular diagnostic on placental blood should qualify as “placental malaria”.

Major comments

1. The approaches are clearly described. Where I disagree with the authors is in the classification, in the abstract and text, of women positive by PCR or IMRS, as having “placental malaria”. Unless and until it is confirmed that infections diagnosed by IMRS represent true malaria infections it seems advisable to use a different and distinct terminology in these cases. The technique of IMRS does seem to detect infections or parasite DNA not picked up on histology; presumably these would include both nonsequestered ring stage parasites “passing through” the placenta and sequestered parasites. The former are generally not visible on histology. It may also include non-viable parasite DNA although that is not established.
2. Related to this in the discussion the authors assert that “more sensitive tests… are critical for placental malaria research and clinical purposes”. IMRS seems considerably better than RDT for diagnosis of infection, but the importance of the detected infections needs to be established. This would depend on the circumstance s e.g. pre-elimination vs high transmission such as here.
3. In the methods they describe classifying placental malaria based on histology. These definitions should be better aligned with the results and with Figure 3. Active comprising acute and chronic (or the terminology the authors use) is clearer.
4. Data analysis: the sample size calculation is unclear. Is the “placental malaria rate” active infection, or any infection? The statement also implies the population size was included in sample size calculation. The sample size in section 2.6 is also difficult to reconcile to the use of 59 samples in section 3.4.
5. Results, section 3.4. The presentation of the comparisons of PCRs, IMRS and histology are not very easy to follow. Given the emphasis the authors place on IMRS it would be helpful to present not just the instances in which it detected placental infection but also those in which it failed.
6. Results, figure 3: please add the numbers contributing to C and D. In 3A the observation that some women received 7 or 8 doses, if accurate, would be concerning, but it is not discussed. 3B: Is this just those with one or more parasite detected? What are the lines indicating? Please clarify in the legend
7. Discussion: The authors report that over 80% of residents of highly endemic regions are

malaria infected but this seems extreme, and does not agree with the cited reference which states “Pf positivity rate was 7.1% (n = 199/2,801) and 9.8% (n = 274/2,801) by standard mRDT and ultrasensitive qPCR, respectively.”

8. Do multiple biopsies lead to higher hit rates for placental infection diagnosis by histology? The authors suggest this but are there studies of multiple sampling that directly test this? Could the authors’ own sample set evaluate this question?
9. Does iso-IMRS detect past infection? The authors could also include this analysis. Whether or for how long DNA persists in detectable form on hemozoin post infection, as the authors suggest, is to my understanding not known. Again, this finding may instead represent non-sequestered parasites.

Minor comments:

In the last paragraph of the introduction, the authors use the terms “asymptomatic malaria” and “unsuspected malaria”. Please avoid using “malaria” when “parasitaemia” or “infection” is meant, malaria is a clinical disease.

Participants: please explain what is meant by “history of malaria infection”.

In the methods the supplier of a reagent needs only to be provided on first mention.

Results section 3.4: the term “malaria in pregnancy positive” is unfortunate. Positive for parasites in peripheral blood is more conventional and clearer.

Reference 5: the full citation of the book in which this is a chapter is needed.

Is the work clearly and accurately presented and does it cite the current literature?
Yes

Is the study design appropriate and does the work have academic merit?
Yes

Are sufficient details of methods and analysis provided to allow replication by others?
Yes

If applicable, is the statistical analysis and its interpretation appropriate?
Partly

Are all the source data underlying the results available to ensure full reproducibility?
Yes

Are the conclusions drawn adequately supported by the results?
Partly

Competing Interests: No competing interests were disclosed.

Reviewer Expertise: malaria in pregnancy and placental malaria

I confirm that I have read this submission and believe that I have an appropriate level of expertise to confirm that it is of an acceptable scientific standard, however I have significant reservations, as outlined above.